

Participants

The study sample comprised of 79 consecutive patients who underwent MP-CPC at the Wills Eye Hospital from March 23, 2014 to June 23, 2016 and who had at least 3 months of follow-up. Patients had uncontrolled glaucoma as defined by IOP above target or evidence of disease progression despite maximal tolerated medical therapy. Patients were enrolled for treatment with MP-CPC at the discretion of the treating physician, but generally had already failed or were not candidates for incisional glaucoma surgery. The study excluded the following: patients 20 years of age or below, patients who had undergone previous intraocular surgery or ocular laser treatment within 2 months of enrollment, patients who had undergone previous CW-CPC within 1 month of enrollment, patients with significant scleral thinning as defined by greater than 1 clock hour, patients with any medical condition who would preclude the subject from providing reliable and valid data, patients enrolled in other prospective clinical trials, and albino patients.

Treatment

Patients underwent MP-CPC using the IRIDEX Cyclo G6 laser with settings of 2000 mW of 810 nm infrared diode laser with a duty cycle of 31.3%, which translated to 0.5 milliseconds of “on time” and 1.1 milliseconds of “off time”. The laser was delivered in a “stop-and-go” pattern (ie, it was held in place for 10 s before being moved to the adjacent section of perilimbal conjunctiva) for 120 to 360 seconds. The 3 o'clock and 9 o'clock positions were avoided, as is standard technique with traditional CW-CPC to avoid the ciliary neurovascular structures. Postoperatively, subjects received Prednisolone 1%—1 drop 4 times a day during the first week followed by a tapering course over an additional 3 weeks.

Outcome Measures

Primary Outcome

Treatment success was defined by an IOP between 6 and 21 mm Hg or a 20% reduction from baseline without an increase in glaucoma medication over baseline. Qualified success was defined as achieving treatment success with the aid of additional antiglaucoma medications. Failure was defined as an inability to meet the criteria for success, need for retreatment > 3 times, or need for incisional glaucoma surgery. Outcomes were assessed at 3 months, 6 months, and the last available follow-up visit for those followed longer than 6 months.

Secondary Outcomes

Anterior chamber inflammation was assessed by slit-lamp biomicroscopy preoperatively and at each postoperative visit and graded according to the Standardization of Uveitis Nomenclature (SUN) grading system.²² Patient charts were reviewed with attention to the occurrence of complications including hypotony (IOP < 5 mm Hg), prolonged inflammation (1+ grade or higher anterior chamber inflammation for ≥ 3 mo), loss of best-corrected visual acuity (BCVA) (≥ 2 lines of Snellen visual acuity for ≥ 3 mo), scleral perforation, phthisis bulbi, and sympathetic ophthalmia. Hypotony was also classified as occurring early (< 1 mo) or late (> 1 mo) postoperatively.

Statistical Analysis

Linear mixed effects models were used to predict the effect of time on IOP, BCVA, and number of medications. Survival analysis was performed to evaluate the time to

treatment success. Finally, univariate logistic regression models were used to evaluate the effect of various covariates on the occurrence of prolonged inflammation. All statistical analyses were performed using SAS software and a *P*-value of <0.05 was considered to indicate statistical significance.

RESULTS

Eighty-two patients underwent MP-CPC with 1 attending surgeon (M.R.M.) at the Wills Eye Hospital from March 23, 2014 to June 23, 2016. Three patients were excluded due to <3 months of follow-up data available, resulting in 79 eyes of 79 patients included in the analysis. The average age of the study cohort was 70.2 years and 48 patients (61%) were female. Patients generally had glaucoma that was refractory to other management approaches. The cohort had a mean BCVA of 20/200 and mean IOP of 31.9 ± 10.2 mm Hg on 2.3 ± 1.2 medications at baseline. Patients had undergone an average of 1.2 ± 0.9 glaucoma surgeries and 1.0 ± 0.7 other ocular surgeries before MP-CPC. Other baseline demographic and clinical characteristics of the study cohort are shown in Table 1.

Eyes received a mean treatment time of 300 ± 42 seconds with a minimum of 120 seconds and maximum of 360 seconds. Follow-up time ranged from 3 to 25 months after MP-CPC, with a mean follow-up time of 7.8 ± 4.5 months. Ten eyes (12.6%) received a second application of MP-CPC during the follow-up period and 1 eye received 3 treatments. For eyes receiving retreatment, most (8/10) were retreated between 1 and 2 months after initial MP-CPC. In 2 cases, IOP was controlled for 1 year before retreatment was necessary. Retreatment was performed at the surgeon's discretion, but patients were generally not good candidates for incisional surgery. For eyes receiving >1 MP-CPC treatment, the follow-up period was calculated from the time of the last laser application.

Rates of treatment success, qualified success and failure are shown in Figure 1. Treatment success rate at 3 months was 74.7% with an additional 10.1% of patients meeting the criteria for treatment success with the addition of medications. Treatment success rates dropped to 66.1% at 6 months and were stable through the last follow-up for those patients followed longer than 6 months. Mean IOP was reduced by 51% at last follow-up with an average of 0.8 fewer glaucoma medications for the cohort (Figs. 2, 3). Linear mixed effects models predicting the effect of time on

TABLE 1. Baseline Demographic and Clinical Characteristics

	N (%)
Race	
Asian	2 (2.5)
Black	24 (30.4)
Latino	5 (6.3)
White	48 (60.8)
Diagnosis	
Primary open angle	40 (50.6)
Chronic angle closure	18 (22.8)
Pseudoexfoliation	9 (11.4)
Uveitic	3 (3.8)
Neovascular	6 (7.6)
Pigmentary	3 (3.8)
Lens status	
Phakic	9 (11.4)
Pseudophakic	63 (79.7)
Aphakic	7 (8.9)

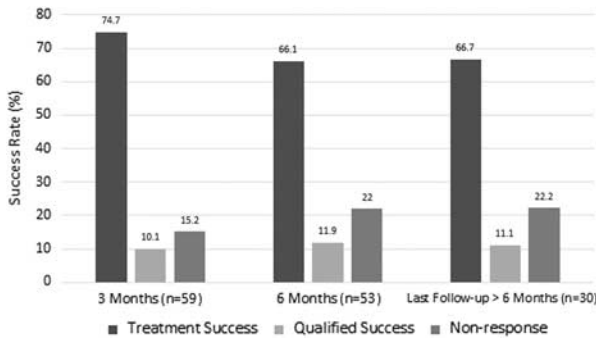


FIGURE 1. Rates of treatment success, qualified success, and nonresponse for the cohort at baseline through the last follow-up.

IOP were not significant with an estimated effect of -0.015 ($P=0.85$). This indicates that posttreatment IOP did not change significantly during the follow-up interval. Linear mixed effects models were significant for the effect of time on logMAR BCVA (estimated effect 0.013, $P=0.02$) and number of medications (estimated effect 0.029, $P=0.02$). A Kaplan-Meier plot showing time to treatment success is shown in Figure 4. Two patients had a baseline visual acuity of no light perception (NLP) and did achieve pain control after MP-CPC.

Complications of MP-CPC included 7 patients with hypotony (8.8%), including 6 patients with early hypotony (IOP < 5 mm Hg within the first postoperative month). Four of these patients had persistent hypotony and 1 additional patient developed hypotony after the first postoperative month, resulting in 5 patients with late hypotony. Additional complications included 21 patients with prolonged anterior chamber inflammation (defined as 1+ cell or flare for ≥ 3 mo, 26%), 13 patients with loss of ≥ 2 lines of BCVA for ≥ 3 mo (16.5%), 4 patients with macular edema (5%), 2 patients with corneal edema, and 2 patients with phthisis bulbi. No patient developed sympathetic ophthalmia. No cases of mydriasis or loss of accommodation were observed; however, given the retrospective nature of the study, this information was not directly elicited from patients and so may have been overlooked. Patients undergoing retreatment did not seem to be more inclined to complications. Among the 10 patients who underwent retreatment, 3 experienced prolonged inflammation, 1 experienced loss of BCVA for ≥ 3 months, and 1 experienced early hypotony that resolved by 3 months. These rates are similar to the overall cohort.

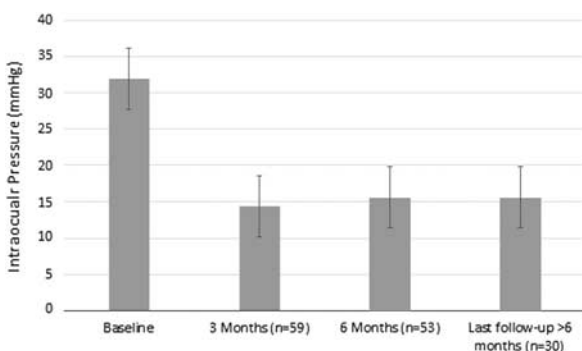


FIGURE 2. Mean intraocular pressure at baseline through the last follow-up.

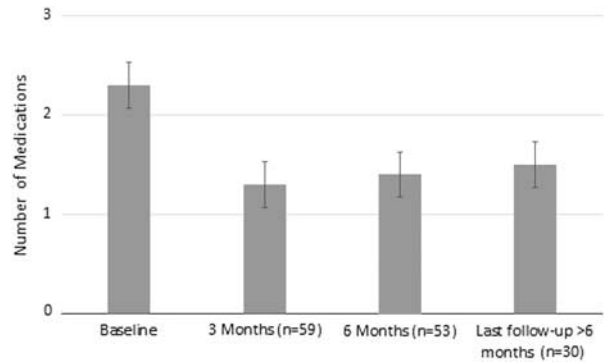


FIGURE 3. Mean number of medications at baseline through the last follow-up.

The clinical characteristics and etiology of vision loss in the 13 patients who lost ≥ 2 lines of BCVA are detailed in Table 2. The 2 patients with baseline vision of NLP were not included in this table as they were not considered to have lost vision as a result of MP-CPC. The frequency of anterior chamber inflammation at each time point is detailed in Table 3. A univariate logistic regression model was carried out to predict the effect of various covariates (age, sex, race, glaucoma diagnosis, diagnosis of hypertension, total energy applied, and preoperative IOP) on the occurrence of prolonged inflammation. The only significant covariate was race, where nonwhite races had 3.6 times greater odds of prolonged inflammation compared with whites (odds ratio, 3.61; 95% confidence interval, 1.27-10.23; $P=0.02$). In addition, there was no difference in IOP control for patients with prolonged inflammation as compared with those patients whose inflammation had resolved at either 3 months ($P=0.41$) or 6 months ($P=0.55$).

Two patients in this cohort developed phthisis after treatment with MP-CPC. The first patient was a 58-year-old Black male with a diagnosis of neovascular glaucoma due to uncontrolled diabetes. He had absolute glaucoma with a baseline vision of NLP and baseline IOP of 69 mm Hg with pain. MP-CPC was carried out with the goal of achieving comfort in this blind painful eye. Standard parameters were used as outlined above and the laser was applied for 120 seconds. He initially had a moderate response to the laser with IOPs ranging from 38 to 48 mm Hg as his postoperative day 1, week 1, and month 1

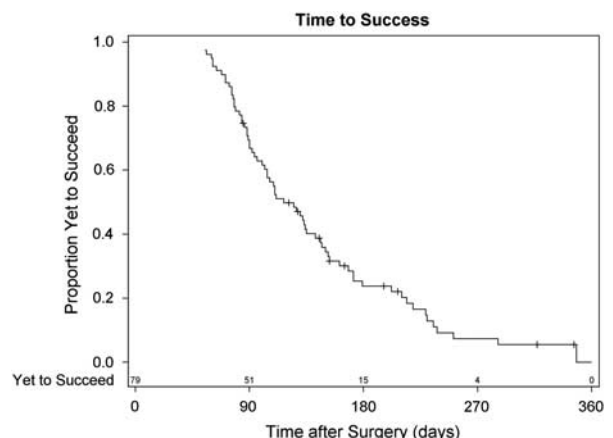


FIGURE 4. Kaplan-Meier curve demonstrating time to success.

TABLE 2. Clinical Characteristics of Patients With Loss of ≥ 2 Lines of BCVA for ≥ 3 Months

Age (y)	Sex	Race	Lens Status	Glaucoma Diagnosis	Ocular Comorbidities	Baseline BCVA	Final BCVA	Etiology of Vision Loss
74	Male	Black	Pseudophakic	POAG	None	20/100	CF	Prolonged inflammation
80	Female	White	Pseudophakic	PXFG	None	20/40	CF	Macular edema, corneal edema
57	Male	Black	Phakic	POAG	None	20/25	20/400	Cataract secondary to severe inflammation
77	Male	Black	Pseudophakic	CACG	Central retinal vein occlusion with macular edema	20/80	20/400	Macular edema
88	Female	White	Pseudophakic	CACG	None	20/40	20/80	Prolonged inflammation
64	Male	White	Pseudophakic	Pigmentary	Retinal detachment	20/20	20/30	Macular edema
78	Female	Black	Pseudophakic	POAG	None	20/40	20/200	Prolonged inflammation
77	Female	White	Pseudophakic	CACG	None	20/25	20/200	Macular edema, prolonged inflammation
64	Female	Black	Aphakic	POAG	None	20/30	20/200	Hypotony maculopathy
71	Male	White	Pseudophakic	Pigmentary	Epithelial downgrowth	20/80	20/400	Corneal edema
60	Female	White	Pseudophakic	POAG	Iridocorneal endothelial syndrome	20/25	CF	Hypotony
83	Female	White	Pseudophakic	PXFG	None	CF	LP	Hypotony
64	Female	Black	Aphakic	POAG	Nanophthalmos	20/30	HM	Hypotony with phthisis

BCVA indicates best-corrected visual acuity; CACG, chronic angle-closure glaucoma; CF, count fingers; POAG, primary open-angle glaucoma; PXFG, pseudoexfoliation glaucoma.

visits. At his postoperative month 3 visit, his IOP had decreased to 2 mm Hg and he had a shrunken globe consistent with phthisis.

The second patient was a 64-year-old Black female with a history of sarcoidosis and nanophthalmos. She was bilaterally aphakic due to complicated cataract surgery as a young adult. Her baseline vision was 20/30 with contact lens correction, and baseline IOP in her study eye was 25 mm Hg on 4 topical glaucoma medications. She had not had previous glaucoma surgery. MP-CPC was carried out due to her aphakia and high risk for complications with incisional surgery. The laser was applied using standard parameters for 180 seconds to both the superior and inferior conjunctival hemifields. IOP was 16 mm Hg at her postoperative day 1 visit and her vision was stable. By postoperative month 1, IOP had decreased to 2 mm Hg and her vision was 20/200. She had a formed but moderately shallow anterior chamber, macular folds, and moderate peripheral choroidal detachments at this time. Over the next year, the patient was placed on atropine and topical steroids. She also received several anterior chamber reformations with viscoelastic and 4 subtenons kenalog injections. Despite these interventions, her IOP was stable at 2 to 3 mm Hg and vision declined to hand motions. The eye became phthisical with apparent shrinkage and scleral thickening, however the cornea remained clear. Ultrasound biomicroscopy (UBM), carried out at 1 year after MP-CPC, confirmed a persistent

shallow choroidal detachment with a small cyclodialysis cleft at the 1 o'clock position. At 13 months postoperation, a cyclodialysis cleft repair was undertaken via an external approach. Repeat UBM after the repair confirmed the small cyclodialysis cleft was closed, however the IOP did not improve and the eye remained phthisical.

DISCUSSION

In this cohort of patients with refractory glaucoma and multiple ocular comorbidities, MP-CPC was shown to be an effective method of lowering IOP. Treatment success rates were 75% at 3 months, 66% at 6 months, and 67% at last follow-up. Linear mixed effects models predicting the effect of time on IOP were not significant, indicating that any IOP lowering effect of the MP-CPC was observable by 3 months and did not deteriorate during the study period for those patients followed for longer than 3 months.

These success rates are consistent with prior studies. Tan et al¹⁶ observed treatment success (defined as IOP <21 mm Hg or a 30% reduction in IOP) in 80% of their 40 MP-CPC treated eyes after 18 months. In their comparative study, Aquino and colleagues observed treatment success (defined as IOP between 6 and 21 mm Hg and at least 30% reduction in IOP) in 75% of 24 MP-CPC treated eyes after 12 months and in 52% of treated eyes after 18 months. With regard to the CW-CPC treatment arm of this study, researchers observed success in 29% of the 24 CW-CPC treated eyes after 12 months and in 30% of CW-CPC treated eyes after 18 months.²⁰

In the above studies, there was no incidence of hypotony or phthisis and only 1 case of vision loss with MP-CPC treatment. These studies also reported significantly lower rates of postoperative inflammation with only 1 patient experiencing anterior chamber inflammation for longer than 1 month after surgery. Our study population had significantly higher

TABLE 3. Frequency of 1+ Grade or Higher Anterior Chamber Inflammation

	N (%)
Baseline (n = 79)	2 (2.5)
3 mo (n = 59)	21 (35.6)
6 mo (n = 53)	14 (26.4)
Last follow-up > 6 mo (n = 30)	7 (23.3)

complication rates including 7 patients with hypotony (6 early and 5 late), 21 patients with prolonged anterior chamber inflammation for ≥ 3 months, 13 patients with loss of ≥ 2 lines of BCVA for ≥ 3 months and 2 patients with phthisis. This may be related to differences in study populations. Our cohort generally had advanced glaucoma, complex ocular histories, and poor baseline visual acuity. These 2 previous studies on MP-CPC also applied significantly lower energy levels. Specifically, both Tan and colleagues and Aquino and colleagues applied the laser for a total of 100 seconds in a painting motion across the perilimbal conjunctiva. Our hospital used similar settings in the earliest applications of MP-CPC, however they were abandoned when they were found to result in insufficient IOP reduction. This study cohort received on average 300 seconds of MP-CPC application and no patient received <120 seconds of treatment time. Although this may be a pertinent factor, it is important to note that one of the patients who developed phthisis received this lowest level of application time (120 s).

Only one other group has published their initial experience with MP-CPC. Emmanuel et al²³ reported a similar level of IOP reduction (41.2% at an average follow-up time of 4.3 mo) and also a similar complication rate, including 46% of eyes with persistent inflammation at 3 months and 41% of eyes with loss of at least 1 line of BCVA. Patients in this study received an average treatment time of 320 seconds.

Limitations of our study include its moderate sample size and incomplete data at each follow-up interval. Because of the tertiary care referral center at which this study was undertaken, many patients followed-up locally for at least some postoperative visits. Although every effort was undertaken to retrieve these data, some records could not be obtained and some patients were simply lost to follow-up. This may have prejudiced the data towards higher apparent complication rates and lower success rates, as patients with an uneventful postoperative course are less likely to return to the tertiary care referral center for long-term follow-up. In addition, these results may not be generalizable to community-based glaucoma practices as most patients in this study had advanced or refractory glaucoma and multiple ocular comorbidities.

In conclusion, this retrospective cohort study demonstrated that MP-CPC is an effective approach for reducing IOP in glaucoma that is refractory to medical management. We describe a broader range of complications than has previously been reported for MP-CPC, possibly related to longer treatment times which are necessary to achieve reasonable success rates in advanced glaucoma. Given the association of nonwhite race with a higher incidence of prolonged inflammation, it would be reasonable to use shorter treatment times in heavily pigmented patients with the understanding that repeat treatment may be needed later should this initial approach be ineffective. Shorter treatment times or alternative therapies should also be considered in patients with nanophthalmos. It is well known that nanophthalmic eyes are predisposed to choroidal detachments and in 1 recent case series of nanophthalmic patients who underwent CW-CPC, all 4 patients developed postoperative choroidal detachments.²⁴ Finally, shorter treatment times may also be advisable in patients with good vision at baseline, given the not infrequent incidence of vision loss in this study. Irrespective of the laser parameters selected, all patients who undergo MP-CPC should be advised that these complications may occur. Additional studies are needed to directly compare the efficacy and safety profile of MP-CPC to that of CW-CPC in patients with advanced glaucoma.

REFERENCES

1. Quigley HA. Number of people with glaucoma worldwide. *Br J Ophthalmol*. 1996;80:389–393.
2. Schlote T, Derse M, Rassmann K, et al. Efficacy and safety of contact transscleral diode laser cyclophotocoagulation for advanced glaucoma. *J Glaucoma*. 2001;10:294–301.
3. Oguri A, Takahashi E, Tomita G, et al. Transscleral cyclophotocoagulation with the diode laser for neovascular glaucoma. *Ophthalmic Surg Lasers*. 1998;29:722–727.
4. Mistlberger A, Liebmann JM, Tschiderer H, et al. Diode laser transscleral cyclophotocoagulation for refractory glaucoma. *J Glaucoma*. 2001;10:288–293.
5. Bloom PA, Tsai JC, Sharma K, et al. Cyclodiode. *Ophthalmology*. 1997;104:1508–1520.
6. Kosoko O, Gaasterland DE, Pollack IP, et al. Long-term outcome of initial ciliary ablation with contact diode laser transscleral cyclophotocoagulation for severe glaucoma. *Ophthalmology*. 1996;103:1294–1302.
7. Ho CL, Wong EY, Chew PT. Effect of diode laser contact transscleral pars plana photocoagulation on intraocular pressure in glaucoma. *Clin Exp Ophthalmol*. 2002;30:343–347.
8. Liu GJ, Mizukawa A, Okisaka S. Mechanism of intraocular pressure decrease after contact transscleral continuous-wave Nd:YAG laser cyclophotocoagulation. *Ophthalmic Res*. 1994;26:65–79.
9. Pastor SA, Singh K, Lee DA, et al. Cyclophotocoagulation: a report by the American Academy of Ophthalmology. *Ophthalmology*. 2001;108:2130–2138.
10. Spencer AF, Vernon SA. “Cyclodiode”: results of a standard protocol. *Br J Ophthalmol*. 1999;83:311–316.
11. Pantcheva MB, Kahook MY, Schuman JS, et al. Comparison of acute structural and histopathological changes of the porcine ciliary processes after endoscopic cyclophotocoagulation and transscleral cyclophotocoagulation. *Clin Exp Ophthalmol*. 2007;35:270–274.
12. Berger JW. Thermal modelling of micropulsed diode laser retinal photocoagulation. *Lasers Surg Med*. 1997;20:409–415.
13. Ishida K. Update on results and complications of cyclophotocoagulation. *Curr Opin Ophthalmol*. 2013;24:102–110.
14. Ramli N, Htoon HM, Ho CL, et al. Risk factors for hypotony after transscleral diode laser cyclophotocoagulation. *J Glaucoma*. 2012;21:169–173.
15. Vernon SA, Koppens JM, Menon GJ, et al. Diode laser cycloablation in adult glaucoma: long-term results of a standard protocol and review of current literature. *Clin Exp Ophthalmol*. 2006;34:411–420.
16. Tan AM, Chockalingam M, Aquino MC, et al. Micropulse transscleral diode laser cyclophotocoagulation in the treatment of refractory glaucoma. *Clin Exp Ophthalmol*. 2010;38:266–272.
17. Francis BA, Singh K, Lin SC, et al. Novel glaucoma procedures: a report by the American Academy of Ophthalmology. *Ophthalmology*. 2011;118:1466–1480.
18. Meyer JJ, Lawrence SD. What’s new in laser treatment for glaucoma? *Curr Opin Ophthalmol*. 2012;23:111–117.
19. Nabili S, Kirkness CM. Trans-scleral diode laser cyclophotocoagulation in the treatment of diabetic neovascular glaucoma. *Eye*. 0000;18:352–356.
20. Aquino MC, Barton K, Tan AM, et al. Micropulse versus continuous wave transscleral diode laser cyclophotocoagulation in refractory glaucoma: a randomized exploratory study. *Clin Exp Ophthalmol*. 2015;43:40–46.
21. Kuchar S, Moster MR, Reamer CB, et al. Treatment outcomes of micropulse transscleral cyclophotocoagulation in advanced glaucoma. *Lasers Med Sci*. 2016;31:393–396.
22. Jabs DA, Nussenblatt RB, Rosenbaum JT. Standardization of uveitis nomenclature for reporting clinical data. Results of the First International Workshop. *Am J Ophthalmol*. 2005;140:509–516.
23. Emmanuel M, Grover D, Fellman R, et al. Micropulse cyclophotocoagulation: initial results in refractory glaucoma. *J Glaucoma*. 2017;26:726–729.
24. Golan S, Kurtz S. Diode laser cyclophotocoagulation for nanophthalmic chronic angle closure glaucoma. *J Glaucoma*. 2015;24:127–129.